

Long-term Effects of Chronic Achilles Tendon Rupture Treatment, Using Reconstruction with Peroneus Brevis Transfer, on Sports Activities

T Kosaka, K Yamamoto

ABSTRACT

Objective: This study reports long-term effects of chronic Achilles tendon rupture treatment, using reconstruction with peroneus brevis transfer (PBT), on sports activities based on an approximate 10-year follow-up study.

Methods: Twenty patients (6 women and 14 men; mean age, 43 ± 12.85 years at the time of operation) underwent chronic Achilles tendon repair with an average follow-up of 164.05 ± 5.07 months. Seven were involved in competitive sports, 10 participated in recreational activities and three were not involved in any sporting activities. All patients were Asians. Results were assessed using Cybex strength testing and the American Orthopaedic Foot and Ankle Society (AOFAS) Score, the muscle manual test (MMT), sports activities and comprehensive satisfaction assessment.

Results: Cybex strength testing resulted in an average gain of $87.05 \pm 14.83\%$ in dorsiflexion strength (range 65–110%) and $98.05 \pm 9.02\%$ in plantar flexion strength (range 85%–120%). The AOFAS score average was 86.9 ± 7.27 . There were no postoperative re-ruptures, no recurrences and no wound complications. Plantar flexion strength and the AOFAS score were negatively correlated with the age at the time of operation ($r = -0.566$, $r = -0.669$, respectively). Seventeen patients (85%) were level five of MMT in eversion strength. Following treatment, six patients (30%) returned to competitive sports, while 10 (50%) who, prior to the injury and surgery, were involved in recreational activities, returned to similar activities. The relatively younger group tended to continue sport activities as competitive athletes ($p < 0.05$). Significant differences were observed in age at the operation between non-satisfaction group and excellent group ($p < 0.05$). The under 40-year age group tended to show a poor value.

Conclusion: Recreational athletes and non-athletes could return to their sports activities satisfactorily, while young competitive athletes found difficulties in certain actions, especially related to eversion.

Keywords: Chronic Achilles tendon rupture, long-term effects, peroneus brevis transfer, sports activities

Efectos a Largo Plazo del Tratamiento de la Ruptura Crónica del Tendón de Aquiles Mediante Reconstrucción con Transferencia del Peroneo Corto en las Actividades Deportivas

T Kosaka, K Yamamoto

RESUMEN

Objetivo: Este estudio reporta efectos a largo plazo del tratamiento de la ruptura crónica del tendón de Aquiles mediante reconstrucción con transferencia del peroneo corto (TPC) en actividades deportivas, sobre la base de un estudio de seguimiento de aproximadamente 10 años.

Métodos: Veinte pacientes (6 mujeres y 14 hombres; edad promedio, 43 ± 12.85 años en el momento de la operación) fueron sometidos a una reparación de ruptura crónica del tendón de Aquiles con un seguimiento promedio de 164.05 ± 5.07 meses. Siete estaban en medio de competencias deportivas, 10 participaban en actividades recreativas, y tres estaban fuera de toda actividad deportiva. Todos los pacientes eran los asiáticos. Los resultados se evaluaron usando la prueba de Cybex para medir la

fuerza, la puntuación de la escala de la Sociedad Ortopédica Americana de Pie y Tobillo (AOFAS) para la valoración quirúrgica, la prueba muscular manual (PMM), y la evaluación integral de la satisfacción y las actividades deportivas.

Resultados: La prueba de Cybex indicó una ganancia promedio de $87.05 \pm 14.83\%$ en fuerza de dorsiflexión (rango 65–110%) y $98.05 \pm 9.02\%$ en fuerza de flexión plantar (rango 85%–120%). El promedio de la puntuación de la escala de AOFAS fue 86.9 ± 7.27 . No se produjeron re-rupturas postoperatorias, ni recurrencias, ni complicaciones de heridas. La fuerza de flexión plantar y la puntuación de la escala AOFAS fueron puestas en correlación negativa con la edad al momento de la operación ($r = -0.566$, $r = -0.669$, respectivamente). Diecisiete pacientes (85%) alcanzaron el nivel cinco de la PMM en fuerza de eversión. Tras el tratamiento, seis pacientes (30%) se reintegraron a las competencias deportivas, mientras que 10 (50%) que antes de la lesión y la cirugía participaban en actividades recreativas, se reincorporaron a actividades similares. El grupo relativamente más joven tiende a continuar las actividades deportivas como atletas de competencia ($p < 0.05$). Se observaron diferencias significativas en edad en la operación entre el grupo sin satisfacción y el grupo excelente ($p < 0.05$). El grupo por debajo de los 40 años de edad mostró valores más pobres como tendencia.

Conclusión: Tanto los atletas de actividades recreativas como los no atletas, pudieron regresar a sus actividades deportivas satisfactoriamente, mientras que los competidores jóvenes encontraron dificultades en ciertas acciones, en particular las relacionadas con la eversión.

Palabras claves: Ruptura crónica del tendón de Aquiles, efectos a largo plazo, transferencia del peroneo corto, actividades deportivas

West Indian Med J 2011; 60 (6): 629

INTRODUCTION

The number of elderly participating in sports events is on the rise. The Achilles tendon is the most commonly ruptured tendon in the human body. In a society that is rapidly ageing, it is essential to examine the long-term outcomes of treatment of chronic Achilles tendon rupture. Local tendons, such as the peroneus brevis tendons, can be used for repair; some investigators have also reported the use of a free gracilis tendon graft. Allografts and synthetic grafts have also been employed (1–4).

For treating chronic Achilles tendon ruptures, we have employed a modified method of peroneus brevis tendon transfer, using a technique similar to that described by Perez-Teuffer (3) and Turco and Spinella (4). Although each of these treatment methods has been reported to produce moderately satisfactory results from short-and medium-term perspectives, a few studies have reported long-term clinical results for more than 10 years after surgery (5).

We followed-up 20 patients and studied sports activities of chronic Achilles tendon rupture treatment using reconstruction with peroneus brevis transfer (PBT) based on an approximate 10-year follow-up study.

SUBJECT AND METHODS

Between August 1985 and May 1995, 20 patients (6 women and 14 men) underwent chronic Achilles tendon repair and reconstruction using a modified method of peroneus brevis tendon transfer. Diagnosis of old Achilles tendon rupture was made on the basis of comprehensive assessment of factors such as pain, swelling, gap between the tendon ends, the calf squeeze test and the Matles test at the ruptured sites. For

patients whose diagnosis was difficult by these methods alone, ultrasonography and magnetic resonance imaging (MRI) were used in combination. The mean age of the patients was 43 ± 12.85 years (range 22–65 years). The average follow-up was 164.05 ± 5.07 months [range 124–224 months] (Table 1). All subjects were Asians.

All patients examined in this study were admitted to our facility after being diagnosed with sprain and partial tears at other facilities. Among the 20 patients, 17 were competitive or recreational athletes at the time of injury.

Follow-up data were obtained by re-calling each patient for a physical examination. The results were measured using a Cybex strength test, range of motion test and the American Orthopaedic Foot and Ankle Society (AOFAS) Ankle-Hindfoot Scale. A subjective questionnaire was provided to all patients. Cybex testing was performed on a Cybex II® (Cybex Division of Lumex, Ronkonkoma, NY) and an isokinetic system interfaced with Humac® (Computer Sports Medicine, Inc, Waltham, MA). Eversion strength was evaluated by the muscle manual test (MMT) and assessed by the patients' subjective experiences of whether the repair was interfering with exercise performance.

Operative technique and postoperative care

The peroneus brevis tendon was used to augment the repair. In the operative procedure followed by us, an incision of approximately 2 cm was made at the base of the fifth metatarsal to expose, identify and detach the peroneus brevis from the base [Fig.1a] (5). The scarred distal Achilles tendon stump was first freshened and the gap at the stump was then measured by positioning the knee and ankle at 30 and 15

Table 1: Patients characteristics

Patient no.	Age #	Sex	Symptom duration*	Follow-up*	Sports activities	Athletic level
1	22	F	3	124	tennis	competitive athlete
2	25	F	2	178	tennis	competitive athlete
3	27	M	1	126	soccer	competitive athlete
4	33	M	8	177	soccer	competitive athlete
5	33	M	5	175	tennis	recreational athlete
6	33	M	2	191	gymnast	recreational athlete
7	34	M	5	125	tennis	competitive athlete
8	38	M	3	125	tennis	competitive athlete
9	39	F	5	128	tennis	competitive athlete
10	39	F	6	178	volleyball	recreational athlete
11	42	M	3	176	soccer	recreational athlete
12	46	M	24	224	volleyball	recreational athlete
13	49	M	8	126	tennis	recreational athlete
14	50	M	3	180	tennis	recreational athlete
15	50	F	12	191	baseball	recreational athlete
16	55	M	3	188	jogging	non-athlete
17	57	M	7	175	track and field	recreational athlete
18	58	F	2	174	jogging	non-athlete
19	65	M	5	132	track and field	recreational athlete
20	65	M	6	188	jogging	non-athlete
Mean	43.0 \pm 12.85		5.65 \pm 5.07	164.05 \pm 30.23		
Range	22~65		1~24	124~224		

= Age at the time of operation (years)

* = months

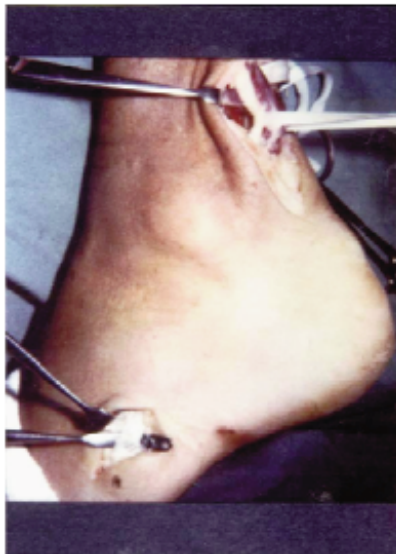

Fig. 1a

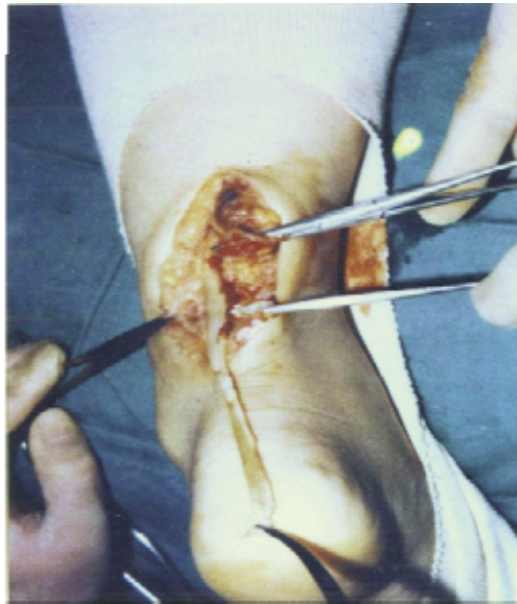


Fig.1b

Fig. 1a: An incision of approximately 2 cm was made at the base of the fifth metatarsal to expose, identify and detach the peroneus brevis tendon from the base.

Fig. 1b: The scarred distal Achilles tendon stump was first freshened and the gap at the stump was then measured by positioning the knee and ankle at 30 and 15 degrees of flexion, respectively.

degrees of flexion, respectively. The detached portion was then pulled from the peroneus tendon groove up to the wound of the Achilles tendon and the central side was detached until near the site of muscle tendon transfer [Fig. 1b] (5). The freshened distal Achilles tendon stump was sutured depending on the size of its gap, applying end-to-end suturing if possible (eight patients). If that was not possible, the gastrocnemius tendon was inversed on the central side and a pedunculated fascia flap was then created and sutured with the stump of the Achilles tendon on the peripheral side (five patients), or the stump was sutured by V-Y lengthening [seven patients] (6–8). Importantly, at this point, the size of the gap must be considered in choosing the suture method. After suturing the distal stumps by one of the above techniques, the already detached peroneus brevis was passed intratendinously from lateral to medial on the peripheral side of the Achilles tendon; it was pulled medially to the central side and the peroneus brevis was then anchored under adequate tension to the Achilles tendon by a side-to-side interrupted suture at 30 and 15 degrees of knee and ankle flexion, respectively. Next, the wound was closed by multilayered suturing [Fig. 2 a, b] (5).

week, partial weightbearing was started with crutches on both sides and the leg immobilized in a below-knee cast with a heel. Passive exercises and full weightbearing were allowed at five or six weeks. The patients were allowed to gradually shift from jogging to running. Rehabilitation was programmed, aiming at a return to sport activities by about six months postoperatively (5).

Statistical analysis

We calculated the correlation coefficients, age at the time of operation against plantar flexion strength and AOFAS. Statistical analysis was performed by testing two groups using the Mann-Whitney U test. Repeated measures of analysis of variance (ANOVA) with Student-Newman-Keuls post hoc test was used to compare age at the time of operation among the groups. The statistical analysis was performed three times and the results are shown as average values. The level of significance was set at $p < 0.05$ for all analyses.

RESULTS

Results from all testing parameters are shown in Table 2. No difference in the average range of ankle motion was found between the operative and non-operative sides in 17 patients

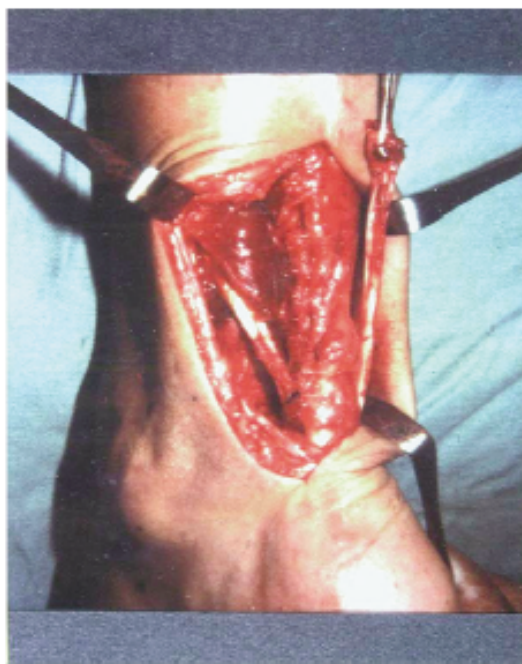


Fig. 2a

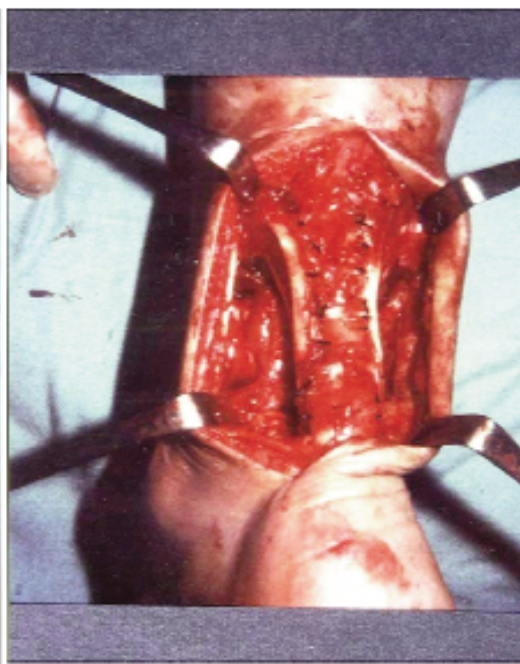


Fig. 2b

Fig. 2a, b: The tendon was pulled medial to the central side and the peroneus brevis was then anchored under adequate tension to the Achilles tendon by a side-to-side interrupted suture at 30 and 15 degrees of knee and ankle flexion, respectively.

Postoperative management

After surgery, the leg (thigh and below) was immobilized in a cast with the knee and ankle at 30 and 15 degrees of flexion, respectively, for two non-weightbearing weeks. In the third

(85%), while the other three patients (15%) were unable to perform more than 10 degrees of ankle dorsiflexion. Cybex strength testing resulted in an average gain of $87.05 \pm 14.83\%$ in dorsiflexion strength (range 65%–110%) and

$98.05 \pm 9.02\%$ in plantar flexion strength (range 85%–120%). The AOFAS score average was 86.9 ± 7.27 . There were no postoperative re-ruptures, no recurrences and no wound complications. Plantar flexion strength and the AOFAS score were negatively correlated with the age at the time of operation [$r = -0.566$, $r = -0.669$, respectively] (Fig. 3a, b). Significant differences in age at the time of operation were observed between the non-athlete and competitive

Among the competitive athletes, the ability to make a side pass was curtailed in soccer players, and the extent of flank movement was reduced in tennis players.

DISCUSSION

Various procedures have been described to repair chronic Achilles tendon ruptures. Most involve bridging the gap with either autologous or synthetic material. Good to excellent

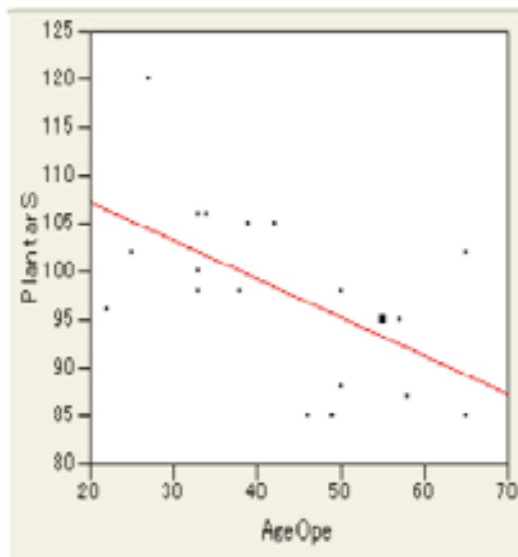


Fig. 3a

Fig 3a: A significant inverse correlation was observed between plantar flexion strength and age at the time of operation ($r = -0.566$, $p = 0.0115$).

Plantar S = plantar flexion strength; Age Ope = age at the time of operation (years)

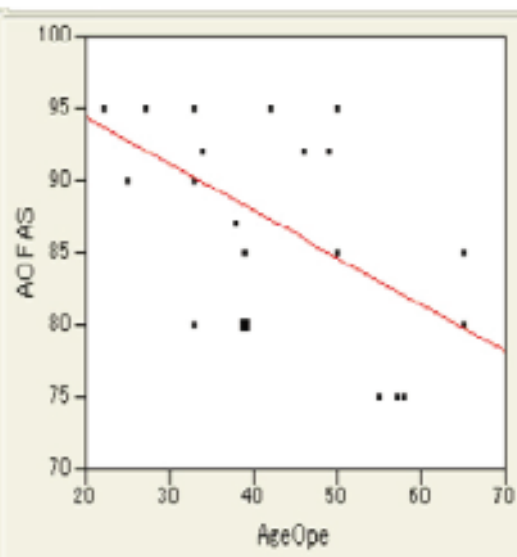


Fig. 3b

Fig 3b: A significant inverse correlation was observed between the AOFAS score and age at surgery ($r = -0.699$, $p = 0.0033$).

AOFAS = American Orthopaedic Foot and Ankle Society; Age Ope = age at the time of operation (years)

groups ($p < 0.05$). The under-40-year age group tended to continue sport activities as competitive athletes (Fig. 4a). Significant differences were observed in age at the time of operation between the non-satisfaction group and the excellent group ($p < 0.05$). The under 40-year age group tended to show a poor value. The over 40-year age group at operation achieved fully satisfactory results (Fig. 4b).

Following treatment, six patients (30%) have been continuing sport activities as competitive athletes, while 10 (50%) have been continuing as recreational athletes. Sports activity correlated with the age at the time of operation, and the younger group tended to continue sport activities as competitive athletes. Seventeen patients (85%) were level five of MMT in eversion strength (Table 2).

results have been reported in 73%–97% of patients, depending on the pathology encountered (1, 8–10). However, all these treatment methods encounter difficulties such as long-term fixation in plaster casts, interrupted blood circulation after tendon transplantation, deformation and atrophy of the triceps surae as well as cicatricial contracture at the surgical wound (5).

Many middle-aged people participate in sports, and the number of sports events for the elderly is on a rise. Hence, we used the peroneus brevis tendon for augmentation. White and Kraynick (11) first described the use of the peroneus brevis tendon, and their procedure was later modified by Perez-Teuffer (3).

The peroneus brevis technique reported by those authors involved re-routing the peroneus brevis tendon

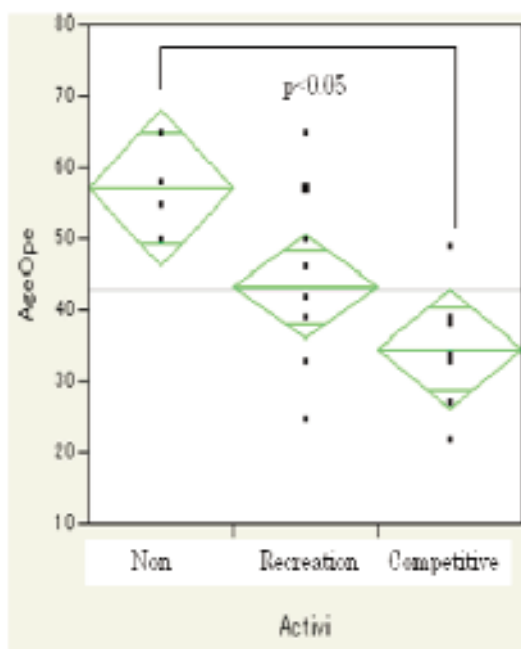


Fig 4a

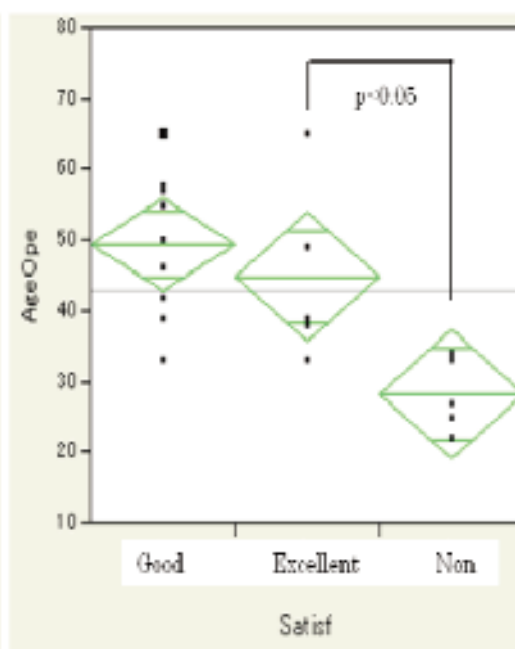


Fig 4b

Fig 4a: Significant differences in age at the time of operation were observed between the non-athlete and competitive groups ($p < 0.05$). The under 40-year age group tended to continue sport activities as competitive athletes.

Non = non-athlete; Age Ope = age at the time of operation (years); Activi = sport activities

Fig 4b: Significant differences were observed in age at the time of operation between non-satisfaction group and excellent group ($p < 0.05$). The under 40-years age group tended to show a poor value. At operation, patients over 40 years achieved fully satisfactory results.

Satisf = satisfaction; Non = non-satisfaction

through a drill hole in the calcaneus in a lateral to medial direction with the remaining tendon sutured to the proximal medial stump of the Achilles tendon, thereby making a dynamic U configuration. Turco and Spinella have reported the outcomes for 40 patients treated by a modification of this technique (4). Perez-Teuffer has reported the outcomes for 30 patients, of whom 28 had excellent results and two had good results (3).

Although there is no evidence that augmentation using the peroneus brevis tendon results in a completely functional outcome, we can at least conclude that the peroneus brevis tendon served as an autogenous tendon graft during the healing process. In addition, our results were clearly more favourable than the 10-year record for patients whose surgeons did not employ the augmentation procedure performed at our facility (data not shown), suggesting that augmentation using the peroneus brevis tendon alone may have advantages. Other orthopaedic surgeons argue that the peroneus brevis tendon should be preserved in adolescent and middle-aged high-level frontline athletes. We are aware of the importance

of eversion for athletes and believe that the peroneus brevis tendon should be preserved in high-level performing athletes. Therefore, since 2000, we have used the peroneus brevis tendon as well as flexor hallucis longus on a per-case basis for operations in patients of chronic Achilles tendon ruptures.

Some recent studies have reported the effectiveness of peroneus brevis tendon transfer on chronic Achilles tendon ruptures. For instance, McClelland and Maffulli (12) approached the Achilles tendon medially and pulled the stump of the peroneus brevis tendon through the inferior peroneal retinaculum, retaining its blood supply from the intermuscular septum. Miskulin *et al* (13) reported the repair of chronic Achilles tendon ruptures using a combination of peroneus brevis tendon transfer and plantaris tendon augmentation. That technique makes use of the transferred peroneus brevis tendon as the strengthening material. Despite the possibility of residual lateral ankle instability, they found this modification to be a valuable innovation offering an excellent functional outcome, low morbidity and a technical advantage to the surgeon.

Table 2: Results of all testing parameters

Patient No.	Tip-toe stance	Range of motion**	Eversion strength#	Dorsiflexion strength**	Plantar flexion strength**	AOFAS Score	Athletic level
1	yes	no difference	5	74	96	95	competitive athlete
2	yes	no difference	5	85	102	90	recreational athlete
3	yes	no difference	5	110	120	95	competitive athlete
4	yes	no difference	5	104	100	90	competitive athlete
5	yes	no difference	5	82	106	95	recreational athlete
6	yes	no difference	5	103	98	80	recreational athlete
7	yes	no difference	5	92	106	92	competitive athlete
8	yes	no difference	5	100	98	87	competitive athlete
9	yes	no difference	5	85	105	85	competitive athlete
10	yes	no difference	5	71	105	80	recreational athlete
11	yes	no difference	5	100	105	95	recreational athlete
12	yes	no difference	5	68	85	92	recreational athlete
13	yes	no difference	5	87	85	92	recreational athlete
14	yes	no difference	4	96	98	85	non-athlete
15	yes	no difference	5	102	88	95	recreational athlete
Dorsiflexion 0							
16	yes	Plantar flexion 40	4	65	95	75	non-athlete
Dorsiflexion 10							
17	yes	Plantar flexion 45	5	72	95	75	recreational athlete
Dorsiflexion 10							
18	yes	Plantar flexion 45	4	68	87	75	non-athlete
19	yes	no difference	5	105	102	85	recreational athlete
20	yes	no difference	4	72	85	80	non-athlete
Mean				87.05 ± 14.83	98.05 ± 9.02	86.9 ± 7.27	
Range				65~110	85~120	75~95	

= Level of muscle manual test

** = Percentage of uninvolved side, not included for bilateral cases

Some studies have reported effective use of flexor hallucis longus instead of the peroneus brevis tendon (14, 15). Elias *et al* (14) reported a high percentage of satisfactory results for 15 consecutive patients with missed complete Achilles tendon ruptures and 5 cm or larger gaps who underwent reconstruction with V-Y lengthening and flexor hallucis longus tendon transfer through a single incision. Biomechanical measurements included failure load, stiffness, energy-to-peak load and the mode of failure (16). The average failure load was significantly higher in the peroneus brevis group ($p = 0.036$), and there was no significant difference in stiffness and energy-to-peak load between the peroneus brevis and flexor hallucis longus groups. However, some authors argue that the loss of push-off from the hallux may cause difficulty when sprinting (12).

The results demonstrated that recreational athletes and non-athletes could return to their sports activities satisfactorily, while young competitive athletes found difficulties in certain actions, especially related to eversion. For our patients, we evaluated eversion strength only by MMT. We had decided that strength of dorsiflexion and plantar flexion were much more important for activities of daily life and basic sport skills at the amateur level; strengthening these movements could allow elderly patients to return to their own specific sports. However, it should certainly be suggested

that use of the peroneus brevis tendon for reconstruction of chronic ankle instability be avoided, especially for the younger patients. Not all younger patients were able to return to their pre-injury level of play after reconstructive surgery, but their skill was greater than that required for recreational sports.

Because Cybex testing in this study involved dorsiflexion and plantar flexion and not eversion, we have no data to show that there was no significant loss of eversion strength in these patients. When a major tendon is sacrificed, it is possible to test the foot and ankle for the function that the tendon performed both before and after the transfer, and to evaluate accurately what effect losing the pull of that tendon had on the patient.

In summary, recreational athletes and non-athletes could return to their sports activities satisfactorily. Young competitive athletes found difficulties in certain actions, especially related to eversion.

REFERENCES

1. Kato YP, Dunn MG, Zawadsky JP, Tria AJ, Silver FH. Regeneration of Achilles tendon with a collagen tendon prosthesis. *J Bone Joint Surg Am* 1991; **73**: 561–73.
2. Maffulli N, Ajis A, Longo UG, Denaro V. Chronic rupture of tendo Achillis. *Foot Ankle Clin* 2007; **12**: 583–96.

3. Perez-Teuffer A. Traumatic rupture of the Achilles tendon: reconstruction by transplant and graft of the lateral peroneus brevis. *Orthop Clinic North Am* 1974; **5**: 89–93.
4. Turco VJ, Spinella AJ. Achilles tendon ruptures-peroneus brevis transfer. *Foot Ankle* 1987; **7**: 253–9.
5. Imakiire A, Kosaka T, Nagai S, Yamamoto K. Long-term results after repair of chronic achilles' tendon rupture using the modified Teuffer method. *Jpn J Orthop Sports Med* 2004; **23**: 292–9.
6. Abraham E, Pankovich AM. Neglected rupture of the Achilles tendon: treatment by V-Y tendinous flap. *J Bone Joint Surg Am* 1975; **57**: 253–5.
7. Arner O, Lindholm A. Subcutaneous rupture of the Achilles tendon; a study of 92 cases. *Acta Chir Scand* 1959; **116 (Suppl 239)**: 1–51.
8. Christensen I. Rupture of the Achilles tendon: analysis of 57 cases. *Acta Chir Scand* 1953; **106**: 50–60.
9. Lidman D, Nettleblad H, Berggren A, Rajan S. Reconstruction of soft tissue defects including the Achilles tendon with free neurovascular tensor fascia lata flap and fascia lata. *Scand J Plast Reconstr Surg* 1987; **21**: 213–8.
10. Wilcox DK, Bohay DR, Anderson JG. Treatment of chronic Achilles tendon disorders with flexor hallucis longus tendon transfer/augmentation. *Foot Ankle Int* 2000; **21**: 1004–10.
11. White RK, Kraynick BM. Surgical uses of the peroneus brevis tendon. *Surg Gynecol Obstet* 1959; **108**: 117–21.
12. McClelland D, Maffulli N. Neglected rupture of the Achilles tendon: reconstruction with peroneus brevis tendon transfer. *Surgeon* 2004; **2**: 209–13.
13. Miskulin M, Miskulin A, Klobucar H, Kuvalja S. Neglected rupture of the Achilles tendon treated with peroneus brevis transfer: a functional assessment of 5 cases. *J Foot Ankle Surg* 2005; **44**: 49–56.
14. Elias I, Besser M, Nazarian LN, Raikin SM. Reconstruction for missed or neglected Achilles tendon rupture with V-Y lengthening and flexor hallucis longus tendon transfer through one incision. *Foot Ankle Int* 2007; **28**: 1238–48.
15. Wegrzyn J, Luciani JF, Philippot R, Brunet-Guedj E, Moyen B, Besse JL. Chronic Achilles tendon rupture reconstruction using a modified flexor hallucis longus transfer. *Int Orthop* 2010; **34**: 1187–92.
16. Sebastian H, Datta B, Maffulli N, Neil M. Mechanical properties of reconstructed Achilles tendon with transfer of peroneus brevis or flexor hallucis longus tendon. *J Foot Ankle Surg* 2007; **46**: 424–8.