

# Posterior Ankle Impingement in Fast Bowlers in Cricket

A Mansingh

## ABSTRACT

**Objective:** To determine common features of posterior ankle impingement in fast bowlers in the West Indies and to compare modes of treatment with respect to return to play without pain.

**Methods:** Retrospective analysis of ankle impingement injuries treated in fast bowlers in the West Indies.

**Results:** Six fast bowlers had evidence of os trigonum in the front foot only. Pain was felt on forced plantar flexion and dorsiflexion on front foot landing; no pain was felt with running. Four had large os trigonum on radiographs, and one was only detectable on Magnetic Resonance (MRI) Imaging. The condition resolved in two bowlers with low workloads who had injections with steroid. The remainder had surgical excision which led to recovery.

**Conclusion:** This injury is being seen increasingly in fast bowlers. Steroid injections are useful in bowlers with low workloads but surgical excision is recommended in bowlers with heavy workloads. Further investigation is required in the biomechanics of bowling to determine the cause for the increase in this condition.

**Keywords:** Ankle impingement in cricket

# Pinzamiento Posterior del Tobillo en Lanzadores de Críquet Rápidos

A Mansingh

## RESUMEN

**Objetivo:** Determinar rasgos comunes del pinzamiento posterior del tobillo en lanzadores rápidos de West Indies, y comparar modos de tratamiento dirigidos a que puedan volver a jugar sin dolor.

**Método:** Análisis retrospectivo del tratamiento de lesiones por pinzamiento del tobillo en lanzadores rápidos de West Indies.

**Resultados:** Seis lanzadores rápidos presentaban evidencia de os trigonum en el pie delantero solamente. Sentían dolor en la flexión plantar forzada y dorsiflexión al aterrizar con el pie delantero; no sentían ningún dolor al correr. Cuatro tenían os trigonum grandes según podía observarse en las radiografías, y un os trigonum era sólo detectable mediante imagen por resonancia magnética (IRM). La condición se resolvió en dos lanzadores con baja carga de trabajo, que recibieron inyecciones de esteroides. El resto recibió una escisión quirúrgica que condujo finalmente a la recuperación.

**Conclusión:** Este tipo de lesión viene observándose cada vez más en lanzadores rápidos. Las inyecciones de esteroide son útiles en lanzadores con baja carga de trabajo, pero en el caso de aquellos con alta carga de trabajo, se recomienda la escisión quirúrgica. Se requiere más investigación de la biomecánica del lanzamiento en el críquet a fin de determinar la causa del aumento de esta condición.

**Palabras claves:** Pinzamiento del tobillo en el críquet

West Indian Med J 2011; 60 (1): 77

---

From: Division of Sports Medicine, Faculty of Medical Sciences, The University of the West Indies, Kingston 7, Jamaica, West Indies.

Correspondence: Dr A Mansingh, Division of Sports Medicine, Faculty of Medical Sciences, The University of the West Indies, Kingston 7, Jamaica, West Indies. Fax: (876) 977-6714, e-mail: akshai.mansingh@uwimona.edu.jm

## INTRODUCTION

Posterior ankle pain has been associated with athletes who engage in activities involving heavy landings or springing off the foot. It is a collection of conditions that include flexor hallucis longus tenosynovitis, peroneal tenosynovitis and tendinitis, intra-articular loose bodies, ankle synovitis and

disorders with an *os trigonum* (1). A post-traumatic overload syndrome of *os trigonum* was described in ballet dancers, soccer players, javelin throwers and runners attributed to extreme plantar flexion or dorsiflexion of the ankle (1).

There has been a sharp increase in the amount of cricket being played worldwide, which led to an increased incidence of back injuries in fast bowlers, ankle injuries in fielders and muscle strains of both upper and lower limbs (2, 3). Extensive screening and intervention in fast bowlers has led to a decrease in the time lost due to injury. Over the last three seasons in West Indies cricket however, there has been an increase in posterior ankle impingement, most associated with large *os trigonums*. These have been exclusively in fast bowlers, at all levels of cricket.

This paper describes a condition not previously associated with cricket. The sudden increase in incidence suggests that screening and preventative measures may be required for all fast bowlers as was employed in back injuries.

SUBJECTS AND METHODS

Surveillance of cricket injuries has been done in the West Indies since 2003, and all injuries are reported to the medical panel using the international consensus on reporting of cricket injuries (4, 5). Additionally, there is close communication between doctors and physiotherapists who treat cricketers in the 16 countries that comprise West Indies Cricket. Information on posterior ankle pain was retrieved from the database and referrals.

Approval for the study was obtained from the Faculty of Medical Sciences, University of the West Indies/University Hospital of the West Indies Ethics Committee. Written consent was obtained from all of the cases described.

CASE REPORTS

Over the last three years, six male fast bowlers involved in Test, first-class or Under 19 competitions in the West Indies presented with pain in the left ankle (Table). All were right-

Table: Summary of six cases with posterior ankle impingement

| Case      | Age | Level of | Symptoms | Os on | Steroid   | Surgery |
|-----------|-----|----------|----------|-------|-----------|---------|
| Return to |     | cricket  | (months) | X-ray | injection | play    |
| (weeks)   |     |          |          |       |           |         |
| 1         | 23  | WI       | 3        | Yes   | Yes       | Yes     |
| 8         |     |          |          |       |           |         |
| 2         | 26  | WIA      | 6        | Yes   | Yes       | Yes     |
| 8         |     |          |          |       |           |         |
| 3         | 22  | WI       | 3        | Yes   | No        | No      |
| 4         |     |          |          |       |           |         |
| 4         | 24  | WI       | 18       | No    | Yes       | Yes     |

handed and presented with an insidious onset of postero-lateral pain in the landing (left) ankle which progressively got worse. Pain was felt in the posterior ankle on front foot landing (FFL) in four bowlers, on springing off after delivery in one and on both landing and springing off in another.

None felt pain with normal running. Their ages ranged from 19 to 26 years. Cases 1, 2, and 5 had previous lumbar stress fractures as well which all resolved. All fast bowlers had gait assessment done and more had biomechanical gait and foot problems. All had physiotherapy using anti-inflammatory modalities, range of motion and strengthening exercises for four to six weeks off bowling.

Case 1

A twenty-three year old fast bowler had progressive tenderness posteriorly on both medial and lateral aspects of the left ankle, with pain on springing off after delivery (forced plantar flexion) for three months. Investigations were as follows: radiographs (Fig. 1) showing a large *os trigonum*, Tech-




Fig. 1: Lateral radiograph of left ankle showing large posterior os.

netium bone scan showing marked localized uptake at the *os trigonum* and MRI scan (Fig. 2) which revealed *flexor hallucis longus* stenosis and thickening of the posterior capsule.

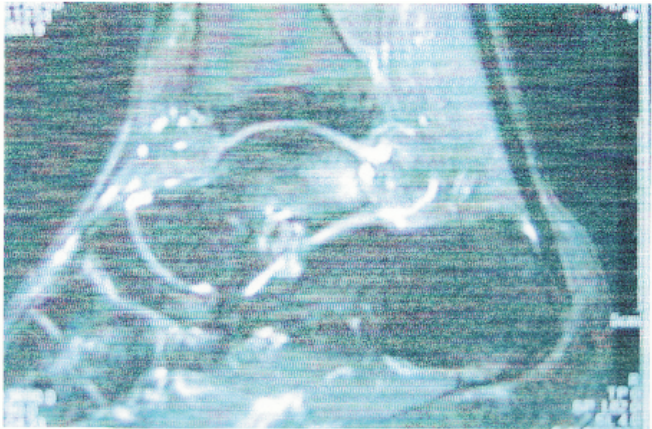


Fig. 2: MRI of left ankle showing os and significant bone reaction.

He was injected with depo-methylprednisone which gave relief for 4 weeks but the symptoms returned with increased bowling loads, ultimately being felt on every deliv-

ery. Following open surgical excision and decompression of his flexor tendons, he returned to Test cricket after 8 weeks, having had physiotherapy and rehabilitation during this period.

#### Case 2

This fast bowler had symptoms in the left foot for six months but was playing professional cricket in England and wished to have it seen at the end of the season. He described pain on actual landing on the left foot (forced dorsiflexion with traction posteriorly). Depo-methylprednisone injection gave relief for three weeks. He has had no symptoms since rehabilitation after open excision. He returned to elite level cricket after 6 weeks.

#### Case 3

Case 3 presented within days of feeling pain. Radiographs revealed a small bony *os*. He responded to a depo-methylprednisone injection and has remained asymptomatic for 2 years. His workload has decreased significantly during this time as he no longer plays for either the West Indies or his territorial team.

#### Case 4

This all-rounder has had a very busy schedule with the West Indies team and was the only case with a history of identifiable trauma as he had strained his lateral ligaments two years prior to developing posterolateral ankle pain. The pain became progressively worse preventing him from bowling painfree. A MRI scan revealed inflammation in the flexor *hallucis longus* (medially) and haematoma in the calcaneal fat pad posterolaterally. There was no evidence of an *os trigonum*. He had a steroid injection and was rested for two months while receiving physiotherapy. His pain returned within four months necessitating the local anaesthetic injections to allow him to complete the season.

A subsequent MRI (a year after the first) showed inflammation around a small developing *os trigonum* (that was not visible on X-rays). He also had strained his posterior talofibular (PTFL) and calcaneofibular (CFL) ligaments but the *flexor hallucis* tendonitis had resolved. He went on to have open excision of the *os trigonum* and thick scar posterior to it, as well as augmentation of the CFL. He was immobilized in a cast for six weeks prior to commencing rehabilitation. He returned to international cricket after seven months.

#### Case 5

This all rounder has played very little first class cricket. He developed symptoms of posterior ankle impingement which resolved with depo-methylprednisone. He has been asymptomatic since. His radiographs however revealed a very large *os trigonum*.

#### Case 6

This national Under 19 representative had no steroid injection but remained symptomatic throughout the season. He had arthroscopic resection at the end of the season in anticipation of a very heavy workload in the following season.

### DISCUSSION

*Os trigonum* was described as early as the 1880s and was recognized as a secondary ossicle centre (second most common in the foot) (6). With bony attachment to the talus, this posterior process is called the Stieda's Process and with no bony attachment, it is called the *os trigonum*. Though it may be congenital, it also occurs as a result of repetitive trauma and is reported to be present in up to 11% of the population (7, 8).

Posterior ankle impingement may be acute or chronic. The time between onset of symptoms and treatment has a bearing on outcome (9, 10). In these cases, Case 3 presented early and was successfully treated non-operatively though his workload was significantly less than all others.

Chronic posterior ankle impingement is seen commonly in ballet dancers where the mechanism was mainly due to forced plantar flexion (1, 11). Bony impingement took place when the *os trigonum* was compressed between the posterior lip of the tibia and superior portion of the *os calcis*, causing a nutcracker-like effect (12). This led to talar and trigonal compression laterally, *flexor hallucis longus* tendonitis medially or both (8, 10).

Forced dorsiflexion leading to traction and avulsion of the lateral talar tubercle has also been shown to contribute to posterior ankle impingement, causing lateral pain. Avulsion forces on the lateral tubercle cause injury to the posterior talofibular ligament and calcaneofibular ligament (1, 10). Robinson (13) described the landing and taking off forces while playing soccer as the likely cause of posterior ankle pain in that sport, similar to case 4.

Repetitive trauma leads to progression of the condition, causing the inflammatory process around the *os trigonum*, and promoting capsular degeneration, *flexor hallucis longus* tendonitis and stenosis. In the cases described, cases 3 and 5 did not continue to play cricket at a high intensity and were the only ones that resolved without surgery.

A combination of both these forces is likely to be the reason for fast bowlers to get it on their landing foot during delivery. That the pain was felt mainly on landing rather than springing off the foot after landing suggests that loaded dorsiflexion had a major effect.

With a sharp increase in the amount of cricket being played over the last decade, the incidence of many cricket injuries has increased. Most dramatic was lower back pain in fast bowlers, which was seen in 33% of schoolboy cricketers and 23% of all cricketers in South Africa (14, 15) and plagued most leading fast bowlers worldwide. Laminar stress fractures were seen in epidemic proportions and were



attributed to be a combination of poor physical strength (or asymmetry of back muscles) of the bowler, faulty biomechanics in delivery and heavy workloads. With screening, training focussing on back and core strengthening, biomechanical adjustments and monitoring of workloads, these injuries have decreased significantly (3, 16, 17).

There was also an increase in acute ankle injuries attributed to new sliding techniques and the resultant crashing into boundary boards. This led to putting a boundary rope away from the boards (3).

The cases described above represent the first report of a rise in chronic ankle injuries previously associated with other sports. The increased incidence may be attributed to the inability of the ankle to recover from the trauma placed on the landing foot especially due to the increased number of playing days at high levels of cricket. Whereas all cases had no evidence of abnormal foot biomechanics, the presence of hypersupination or hyperpronation would clearly hasten impingement. Modern boots used by fast bowlers are low cut and may exaggerate movement at the ankle. This coupled with increased bowling loads and varying ground hardness contribute to greater forces across the ankle. Even variations in foot biomechanics and bowling techniques are more likely to be contributory to ankle injuries than before because of increasing work loads. Ankle ligament injuries have been shown to alter biomechanics, increasing the rate of recurrent sprains (18) and possibly impingement. Only case 4 had a previous documented history of an ankle sprain.

Lateral ankle radiographs were pathognomonic in five of the six cases, especially the four large *os trigonum* (Fig. 1). However, it is noted that the size does not have clinical correlation for treatment or prognosis (18, 19) as was seen in case 5. Whereas the use of bone scans and CT scans can further show functional and structural details respectively, MRI scans (Fig. 2) can show both and also show additional conditions such as ligament injury, chondral damage and inflammation in the posterior capsule or tendons (9, 10, 13). The MRI therefore is recommended as the second line of investigation (after plain radiographs).

The management of posterior ankle impingement ranges from complete non-surgical approaches to surgical excision of the *os* and decompression of stenosed tendons, and repair, augmentation or reconstruction of damaged ligaments. Acute and mild chronic cases are likely to respond to non-operative management. Hamilton (8) suggested a graded approach. When detected in the tendinitis phase, treatment is focussed towards rest, anti-inflammatory drugs and physiotherapy as was seen in case 3. Where this does not help, or there is recurrence, corticosteroid injections are given with immobilization for upto two weeks. Surgery is performed if these measures fail.

Whereas use of non-steroidal anti-inflammatory medication along with ankle strengthening had been shown to be successful in reducing symptoms (18), this has not been the case in fast bowlers, at least with lasting effects. Steroid

injections seem to offer temporary relief. Both of these modalities may be of use in early stages, especially when there is low workload (as in Cases 3 and 5). They also are good temporizing methods in a heavy workload bowler, till a convenient time for surgery can be found to minimize time lost during recuperation. Ultrasound and fluoroscopic assisted injections may enhance effectiveness (13). Whether this has greater benefit than local anaesthetic injections is debatable (20).

Surgical excision is therefore advocated in all fast bowlers with symptomatic *os trigonum*, who are likely to have heavy workloads. This is similar to the suggestions in ballet dancers who had operative management and reported unrestricted movement and occasional pain (21). With no reports of recurrence, surgery is more likely to provide lasting relief. Return to play within two months (cases 1, 2, and 6) after surgical excision was less than the eight months reported previously (1). With increased use of arthroscopic debridement of the *os trigonum*, there is an increased use of the operative option with a reduction time away from the sport (9).

Rehabilitation was based on early restoration of motion and strengthening exercises. Closed-chain balance and proprioception activities, along with peroneal muscle strengthening, improves neuromuscular control of the ankle and was used successfully on dancers (22). In dancers, this led to overall results which were 80% good to excellent and 20% fair to poor. The results were compared in professional *versus* amateur dancers and it was found that an excessive number of the fair to poor results were found in amateur dancers (8).

With an increase in posterior ankle impingement in fast bowlers, it would be worth investigating the biomechanics of bowlers' ankle during bowling to assess if there is some common factor leading to this condition. Videography was used successfully in identifying that mixed actions were likely to lead to stress fractures of the lumbar spine in fast bowlers (23) and could be of similar value in ankle injuries.

## REFERENCES

1. Moushine E, Crevoisier X, Leyvraz P, Akiki A, Dutoit M, Garofalo R. Posttraumatic overload or acute syndrome of the *os trigonum*: a possible case of posterior ankle impingement. *Knee Surg Sports Traumatol Arthrosc* 2004; **12**: 250–3.
2. Mansingh A, Harper L, Headley S, King-Mowatt J, Mansingh G. Injuries in West Indies Cricket 2003–2004. *Br J Sports Med* 2006; **40**: 119–23.
3. Orchard J, James T, Portus M. Injuries to elite male cricketers in Australia over a 10-year period. *J Sci Med Sport* 2006; **9**: 459–67.
4. Orchard J, Newman D, Stretch R, Frost W, Mansingh A, Leipus A. Methods for injury surveillance in international cricket. *J Sci Med Sport* 2005; **8**: 1–14.
5. Orchard J, Newman D, Stretch R, Frost W, Mansingh A, Leipus A. Methods for injury surveillance in international cricket. *Br J Sports Med* 2005; **39**: e22.
6. Lawson J. Radiographic variants in extremities. *Radiology* 1985; **157**: 625–31.
7. McDougall A. *Os Trigonum*. *J Bone Joint Surg* 1955; **37B**: 257–65.

8. Hamilton W. Posterior ankle pain in dancers. *Clin Sports Med* 2008; **27**: 263–77.
9. Abramowitz Y, Wollstein R, Barzilay Y, London E, Matan Y, Shabat S et al. Outcome of resection of a symptomatic Os trigonum. *J Bone Joint Surg* 2003; **85A**: 1051–7.
10. Karasich D, Schweitzer M. The Os trigonum syndrome. *AJR* 1996; **166**: 125–49.
11. Wredmark T, Carlstedt C, Bauer H, Saarok T. Os trigonum syndrome: a clinical entity in Ballet dancers. *Foot ankle* 1991; **11**: 404–6.
12. Mizel MS, Hecht PJ, Marymont JV, Thomas Temple H. Evaluation and treatment of chronic ankle pain. *Jour Bone Joint Surg* 2004; **86A**: 622–32.
13. Robinson P, Bollen S. Posterior ankle impingement in professional soccer players: effectiveness of sonographically guided therapy. *AJR* 2006; **187**: 1053–8.
14. Stretch R. The seasonal incidence and nature of injuries in schoolboy cricketers. *S Afr Med J* 1995; **85**: 1182–4.
15. Stretch R. Cricket injuries: a longitudinal study of the nature of injuries to South African Cricketers. *Br J Sports Med* 2003; **37**: 250–3.
16. Dennis R, Finch C, Farhart P. Is bowling workload a risk factor for injury to Australian junior cricket fast bowlers? *Br J Sports Med* 2005; **39**: 843–6.
17. Portus M, Mason B, Elliott B, Pfitzner M, Done R. Techniques factors related to ball release speed and trunk injuries in high performance cricket fast bowlers. *Sports Biomech* 2004; **3**: 263–84.
18. Maquirrian J. Posterior ankle impingement. *J Am Acad Orthop Surg* 2005; **13**: 365–71.
19. Labs K, Leutloff D, Perkin C. Posterior ankle impingement syndrome in dancers – a short follow up after operative treatment. *Foot Ankle Surg* 2002; **8**: 33–9.
20. Orchard J. Benefits and risks of using local anaesthetic for pain relief to allow early return to play in professional football. *Br J Sports Med* 2002; **36**: 209–13.
21. Marotta J, Micheli L. Os trigonum impingement in dancers. *Am J Sports Med* 1992; **20**: 533–6.
22. O'Loughlin M, Hodgkins C, Kennedy J. Ankle sprains and instability in dancers. *Clin Sports Med* 2008; **27**: 247–62.
23. Elliott B. Back injuries and the fast bowler in cricket. *J Sports Sci* 2000; **18**: 983–91.