

Recurrent Rhinolithiasis: A Case Report with Review of the Literature

M Dogan¹, D Ozdemir Dogan², C Duger³, S Polat⁴, S Muderris⁵

ABSTRACT

Rhinolith is an uncommon nasal mass and a rare entity encountered in clinical practice. The typical symptoms of rhinolith are unilateral nasal obstruction, foul smelling purulent nasal discharge and epistaxis, crusting, swelling of nose or face, anosmia, epiphora and headache. In this report, we present a case of recurrent rhinolith manifesting as an incidental finding on dental radiographs. A 26-year old male patient with a history of long standing halitosis had an operation for rhinolith seven years previously. Rhinolith in the right nasal cavity was diagnosed on rigid endoscopic examination. Rhinolith was removed by using a rigid nasal endoscope under local anaesthesia. To our knowledge, recurrence of rhinolith has not been described previously in the literature.

Keywords: Endoscopy, halitosis, recurrence, rhinolith

Rinolitiasis Recurrente: Reporte de Caso y Revisión de la Literatura

M Dogan¹, D Ozdemir Dogan², C Duger³, S Polat⁴, S Muderris⁵

RESUMEN

El rinolito es una masa nasal poco común y una entidad rara en la práctica clínica. Los síntomas comunes del rinolito son: obstrucción nasal unilateral, secreción nasal purulenta y maloliente, epistaxis, encostramiento, inflamación de la nariz o la cara, anosmia, epífora, y dolor de cabeza. Este reporte presenta el caso de un rinolito recurrente, que se presentara como un hallazgo incidental en una radiografía dental. Un paciente varón de 26 años de edad, con una larga historia de consulta por halitosis con un dentista y un otorrinolaringólogo, fue operado a causa de un rinolito hace siete años. El rinolito en la cavidad nasal derecha, fue diagnosticado mediante un examen endoscópico rígido. El rinolito fue extirpado usando una endoscopia nasal rígida, bajo anestesia local. Hasta donde sabemos, la recurrencia de rinolitos no ha sido descrita previamente en la literatura.

Palabras claves: Endoscopía, halitosis, recurrencia, rinolito

West Indian Med J 2012; 61 (7): 760

INTRODUCTION

Rhinoliths are calcareous concretions around calcinated intranasal foreign bodies within the nasal cavity (1). Rhinolithiasis is a rare and under-diagnosed clinical entity whose aetiology and pathogenesis is poorly understood. Small sized rhinoliths are usually asymptomatic. In these cases, lesions

are mostly encountered by chance in periapical radiographs taken for a dental problem (2, 3). As the rhinolith increases in size, the symptoms may range from unilateral nasal discharge, unilateral purulent rhinitis with or without consecutive sinusitis, facial pain, headache, epistaxis, impairment of nasal breathing ending in complete obstruction, dacryocystitis, otorrhoea (4), fetor, anosmia, palatal perforation (5, 6), and septal perforation (7–9). The diagnosis is established on the basis of the medical history and endoscopic findings; an imaging modality may provide additional information (10). The treatment of choice is surgical removal under local or general anaesthesia (11).

We present a rare case of posteriorly situated recurrent rhinolith treated with the help of a rigid nasal endoscope.

From: ¹Department of Otolaryngology Head and Neck Surgery, Numune Hospital, 58010, Sivas, Turkey, ²Department of Prosthetic Dentistry, Cumhuriyet University School of Dentistry, 58140, Sivas, Turkey, ³Department of Anaesthesiology, Cumhuriyet University School of Medicine, 58140, Sivas, Turkey, ⁴Department of Pathology, Numune Hospital, 58010, Sivas, Turkey and ⁵Department of Otolaryngology Head and Neck Surgery, Cumhuriyet University School of Medicine, 58140, Sivas, Turkey.

Correspondence: Dr C Duger, Department of Anaesthesiology, Cumhuriyet University School of Medicine, Sivas, Turkey. E-mail: cevdetduger@gmail.com

CASE REPORT

A 26-year old man visited the dental clinic with a complaint of halitosis. After the clinical examination, there was no apparent gingivitis, periodontitis, decay or unhygienic restoration to cause halitosis. An ortopantomogram was taken and a radiolucency was noticed in the right nasal cavity (Fig. 1). Patient consultation with an otolaryngologist was recommended.

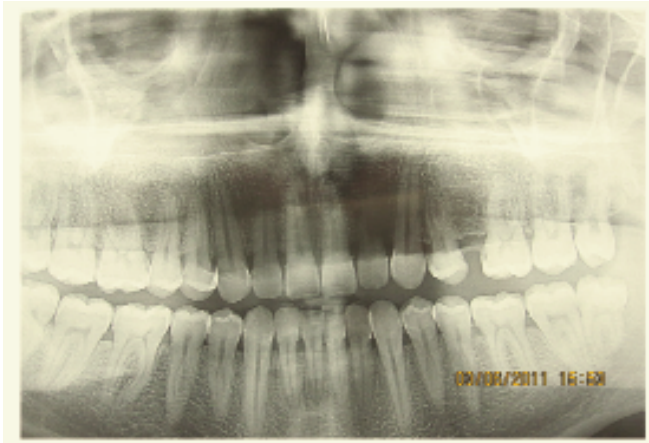


Fig. 1: Ortopantomogram showing radiolucency in the right nasal cavity.

On checking the clinical history by the otolaryngologist, the patient had been operated on seven years previously in the same region for rhinolithis which was thought to be causing severe headache. At the present time, there were no complaints related to the rhinolith in the patient except halitosis. He was unable to recall any history of intranasal foreign body introduction or trauma. An extra oral examination revealed no facial swelling or sensory disturbance. An intranasal examination using a speculum and rhinoscope revealed a greyish-white irregular mass along the floor of the nose just below the inferior turbinate. A computed tomography (CT) was taken and demonstrated radiopacities in the right nasal cavity (Fig. 2).

After proper decongestion with oxymetazoline (oksinal 0.05% spray, Eczacıbaşı, Lüleburgaz, Turkey) and anaesthetizing the nasal cavity with lidocaine 10% (Xylocaine gel, Astra Zeneca), the nasal cavity was evaluated with a 00 rigid nasal endoscope. Endoscopic examination of the nasal cavity revealed an irregular hard foreign body extending from the roof to the floor of the posterior part of the right nasal cavity. Under local anaesthesia, the rhinolith was crushed and removed. The patient made an uneventful recovery.

Macroscopically, the excised mass was cancellous and showed an irregular surface (Fig. 3). Histopathologic sections of the excised mass showed calcification (Fig. 4). The nidus, though, was not identifiable.

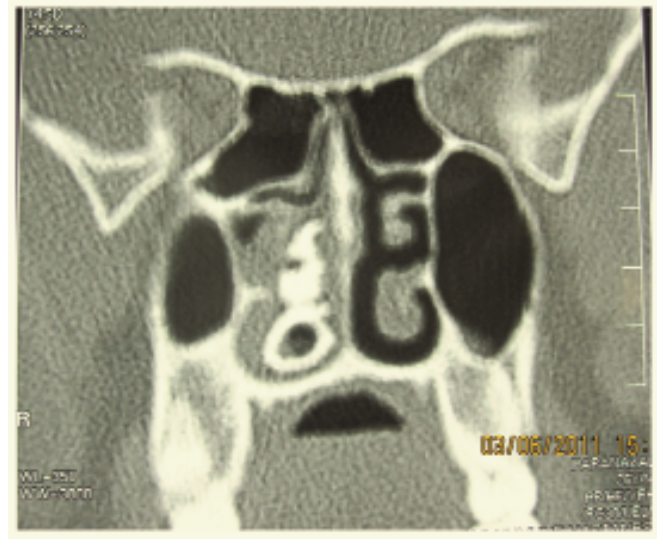


Fig. 2: Computed tomography (CT) scan showing radiopacities in the right nasal cavity.

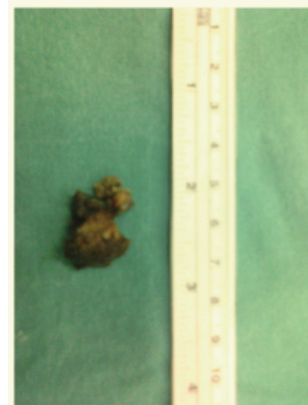


Fig. 3: Macroscopic aspect of rhinolith after endoscopic removal.

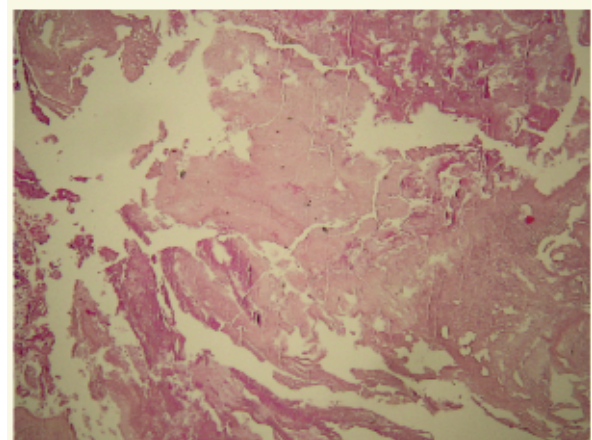


Fig. 4: Histopathologic section of the rhinolith. Calcification is evident.

DISCUSSION

Rhinoliths usually present in the third decade of life and rarely occur in children; females are more commonly affected than males (8, 12). In most cases, the rhinolith is located in the inferior nasal meatus (13). This case is typical with respect to the age of the patient, the location, diagnostic and therapeutic approach for a rhinolith.

The pathogenesis of rhinolith is unclear. It has been mentioned that a foreign body incites a chronic inflammatory reaction, with the deposition of mineral salts. Most foreign bodies are exogenous; rarely, endogenous agents may cause true rhinolith. The most common symptoms of rhinolith are foul smelling purulent nasal discharge, unilateral nasal obstruction and epistaxis. Other symptoms are swelling of nose or face, crusting, epiphora, anosmia and headache (12, 14). Small sized rhinoliths are usually asymptomatic. Although the rhinolith in this case was not small, there were no symptoms except halitosis and it manifested as an incidental finding on dental radiographs.

The first published report of a calcified foreign body in the nose appeared in 1654, in which Bartholini described a stone-hard foreign body that had grown around a cherry stone. The term rhinolith was first coined in 1845 to describe a partially or completely encrusted foreign body in the nose (13). In 1900, MacIntyre gave the first radiological description of a rhinolith. The typical radiological features are radio-opacity with central translucency. On CT scan, it appeared as a homogenous, high-density lesion with smooth mineralization (8, 12). A CT scan is recommended due to its sensitivity in recognizing even small amounts of calcification and it also provides information about adjacent structures and thus helps distinguish rhinoliths from other entities (3, 15). The differential diagnosis should include tori, calcified nasal polyps, impacted teeth, odontoma, mycolith, osteoma, osteosarcoma, ossifying fibroma, haemangioma, chondrosarcoma and syphilitic and tuberculous calcification (3).

Endoscopically controlled surgery can also be immensely helpful in complete and uneventful removal of the rhinolith and in dealing with complications such as sinusitis. It is a cost-effective and more accurate method for diagnosis and treatment (12, 16).

Yasar *et al* conducted a retrospective analysis of 18 cases of rhinolithiasis between 1990 and 2004 (11). All rhinoliths were in the inferior meatus. Patients' complaints were unilateral, foul-smelling rhinorrhoea and nasal obstruction. Five patients also had headache, and two had cleft lip and palate.

Ozdemir *et al* reviewed a total of 21 patients (9 male and 12 female patients; age range 4–63 years) diagnosed with rhinolithiasis (17). The most common symptoms were noted as purulent rhinorrhoea and nasal obstruction. The other symptoms were headache, oral malodour and recurrent epistaxis. Our case had only halitosis as a symptom. Nasal endoscopic examination was used for diagnosis of all

patients. Endoscopic nasal examinations and CT findings revealed that rhinolithiasis was accompanied by sinusitis, chronic vestibulitis, allergic rhinitis, septum deviation and squamous cell carcinoma. Rhinoliths were fully excised by using endoscopic nasal surgery.

Kharoubi presented 20 cases of rhinolithiasis between 1990 and 2007 for consultation. Rhinolithiasis was found in adults (55%), females, patients living in rural areas (66%) with unfavourable socio-economic conditions (18). The diagnosis delay varied between six months and eight years. The examination showed the rhinolith in the form of a grey concretion, primarily unilateral and on the right-hand side in 60% of the patients. Only one bilateral case presented following destruction of the posterior nasal septum. The rhinolith measured between five and 50 mm in diameter with only three associated foreign bodies (15%). The rhinolith was extracted through the natural pathways under local anaesthesia in 60% of the cases. Complications were rare (epistaxis 10%) and favourable progression without recurrence was generally observed after a mean 16 months of follow-up (range six months to 11 years).

In the literature, recurrence after removal of rhinolith has never been reported (3, 19). The present case was an atypical recurrent rhinolith which had been excised seven years previously and gave no symptoms except foul-smelling rhinorrhoea.

In conclusion, we suggest that rhinoliths may reoccur after total removal and foul smelling rhinorrhoea may be the only symptom.

REFERENCES

1. Keck T, Liener K, Strater J, Rozsasi A. Rhinolith of the nasal septum. *Int J Pediatr Otorhinolaryngol* 2000; **53**: 225–8.
2. Appleton SS, Kimbrough RE, Engstrom HIM. Rhinolithiasis: a review. *Oral Surg Oral Med Oral Pathol* 1988; **65**: 693–8.
3. Patil K, Guledgud MV, Malleshi SN. Rhinolith. *Indian J Dent Res* 2009; **20**: 114–6.
4. Hoffmann AJ, Wagenfeld DJH. Rhinolith (nasal stone) associated with chronic otorrhea: a case report. *South African Med J* 1986; **69**: 200–1.
5. Olbrich H. Rhinolith in einem Gaumendefekt. *HNO* 1965; **13**: 116–7.
6. Flood TR. Rhinolith: an unusual cause of palatal perforation. *Br J Oral Maxillofac Surg* 1988; **26**: 486–90.
7. Bicknell PG. Rhinolith perforating the hard palate. *J Laryngol Otol* 1970; **84**: 1161–2.
8. Royal SA, Gardner RE. Rhinolithiasis: an unusual pediatric nasal mass. *Pediatr Radiol* 1998; **28**: 54–5.
9. Kharoubi S. Rhinolithiasis associated with septal perforation. A case report. *Acta Otorhinolaryngol Belg* 1998; **52**: 241–5.
10. Brehmer D, Riemann R. The rhinolith – a possible differential diagnosis of a unilateral nasal obstruction. *Case Report Med* 2010; **2010**: 845671.
11. Yaşar H, Ozkul H, Verim A. Rhinolithiasis: a retrospective study and review of the literature. *Ear Nose Throat J* 2009; **88**: 24.
12. Singh RK, Varshney S, Bist SS, Gupta N, Bhatia R, Kishor S. A case of rhinolithiasis. *Online J Health Allied Scs* 2008; **7**: 7.
13. Polson CJ. On rhinoliths. *J Laryngol Otol* 1943; **58**: 79–116.
14. Aksungur EH, Binokay FB, Bicakci K, Apaydin D, Oguz M, Aydogan B. A rhinolith which is mimicking a nasal benign tumor. *Eur J Radiol* 1999; **31**: 53–5.
15. Burbuk PK, Garstecka A, Betlelewski. Nasal foreign body in an adult. *Eur Arch Otorhinolaryngol* 2005; **262**: 517–8.

16. Ogretmenoglu O. The value of endoscopy in the diagnosis of rhinolith: a case report. *Kulak Burun Bogaz Ihtis Derg* 2003; **11**: 89–92.
17. Özdemir S, Akbas Y, Görgülü O, Selçuk T, Sayar Ç. Rhinolithiasis: review of 21 cases. *Am J Rhinol Allerg* 2010; **24**: 136–9.
18. Kharoubi S. General review of rhinolithiasis. *Ann Otolaryngol Chir Cervicofac* 2008; **125**: 11–7.
19. Shaw LC. Rhinolith of endogenous origin: a rare entity. *Surg Pract* 2007; **11**: 48–50.