

## Spontaneous Rupture of a Varicocoele

WN Chin<sup>1</sup>, M Cadogan<sup>2</sup>, R Wan<sup>2</sup>, L Harrison<sup>2</sup>

### ABSTRACT

*We present the case of a young male with an acute scrotal haematoma due to spontaneous rupture of a spermatic cord varicocoele confirmed by Doppler ultrasonography. After failure of conservative management, surgical exploration was performed with successful evacuation of the scrotal haematoma.*

## Ruptura Espontánea de un Varicocele

WN Chin<sup>1</sup>, M Cadogan<sup>2</sup>, R Wan<sup>2</sup>, L Harrison<sup>2</sup>

### RESUMEN

*Presentamos el caso de un joven con un hematoma escrotal agudo a causa de la ruptura espontánea de un varicocele de cordón espermático, confirmada por medio de una ultrasonografía de Doppler. Luego de que fracasara un tratamiento conservador, se llevó a cabo una exploración quirúrgica con evacuación exitosa del hematoma escrotal.*

West Indian Med J 2009; 58 (5): 488

### INTRODUCTION

Spermatic cord varicocoele is a common condition affecting up to 15% of the post adolescent male population (1). Varicocoele rupture is rarely encountered and often misdiagnosed, but is a recognized cause of spermatic cord haematoma. An acute scrotal haematoma due to varicocoele rupture is an uncommon presentation, with only a few reported cases in the world literature. We present a case of spontaneous varicocoele rupture.

#### Case Report

A 33-year old man presented to the Emergency Room of the Kingston Public Hospital for evaluation of a nontraumatic left scrotal swelling. He initially noticed the painless swelling in the left groin 2 days previously after lifting a heavy piece of furniture. As the swelling gradually progressed, he began experiencing left groin discomfort. The patient had no known bleeding disorder and had no history of prior scrotal swelling or hernia. He was not on any medications.

On examination, he had a markedly swollen and thickened left hemiscrotum with the swelling extending up to the left inguinal canal. Palpation revealed a fluctuant soft tissue mass within the left side of the scrotum displacing the left

testicle anteriorly. The left testis was non-tender and appeared normal, however its posterior aspect could not be palpated. The left spermatic cord could not be distinguished. The right-sided scrotal contents were normal.

Doppler ultrasonography of the scrotum revealed normal testes bilaterally with left-sided varicocoeles and a large left scrotal haematoma. Sonography of the abdomen done concurrently revealed no intra-abdominal pathology. Blood studies, including complete blood count and bleeding time, were normal.

The diagnosis of a scrotal haematoma possibly secondary to a ruptured varicocoele was made. Differentials included haemorrhage from a testicular or para-testicular lesion. Conservative care with scrotal elevation, antibiotics and anti-inflammatory agents was commenced. After five days, there was no improvement in the scrotal swelling or pain and after informed consent scrotal exploration was performed. A left inguinal approach was used and three varicocoeles were found and ligated. The testis was delivered into the wound and about 200cc of clotted blood was evacuated from the left scrotal sac (Figure). Careful examination revealed a haematoma of the spermatic cord with no active bleeding. The testis and epididymis were normal and no masses were found. The testicle was replaced and the incision closed. The post-operative period was uneventful and the patient was discharged from hospital on post-operative day 2. Outpatient follow-up revealed only mild residual induration of the left scrotal skin.

From: <sup>1</sup>Department of Surgery, Radiology, Anaesthesia and Intensive Care, The University Hospital of the West Indies, Kingston 7, Jamaica and <sup>2</sup>Department of Urology, Kingston Public Hospital, Kingston, Jamaica

Correspondence: Dr W Chin, Department of Surgery, Radiology, Anaesthesia and Intensive Care, The University of the West Indies, Kingston 7, Jamaica, West Indies. E-mail: docchin75@gmail.com

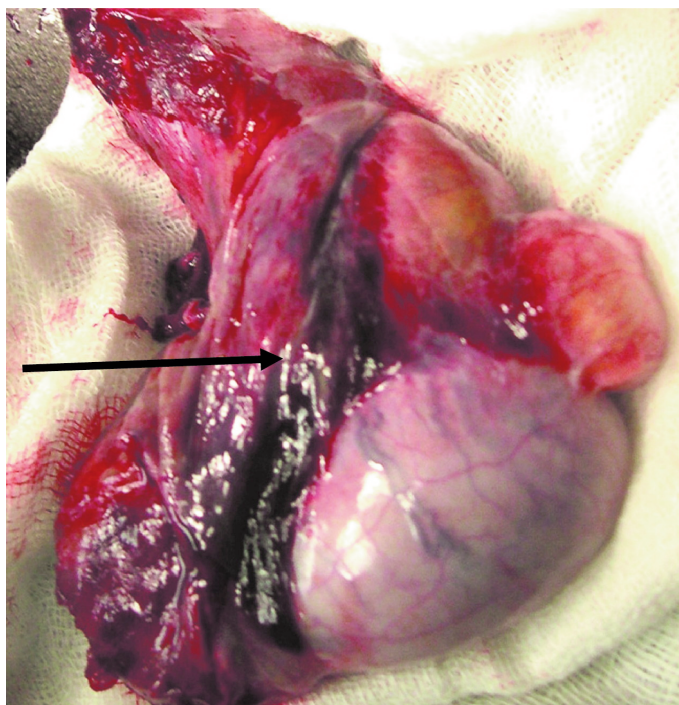


Figure: Left spermatic cord and testicle with haematoma (arrow) within cord extending to superior aspect of testicle.

## DISCUSSION

An acute scrotal haematoma is a recognized but uncommon clinical entity (2). The earliest reports were described as idiopathic spermatic cord haematomas and the presence of a varicocele was not specifically described (3–6). An association was made between straining and acute haemorrhage. Published reports have since associated spermatic cord haematoma with ruptured varicocele (7–12). Ruptured varicocele is most commonly seen in young men, but there has been at least one case report of its occurrence in an elderly man with malignant venous obstruction (12).

Varicocele rupture may occur spontaneously or be due to trauma such as blunt scrotal or abdominal trauma. Events such as the Valsava manoeuvre (*eg* during defecation) and sexual intercourse are documented causes of spontaneous rupture. The pathology involved seems to be that of venous hypertension leading to rupture of the abnormal venous channels (9).

Most cases of varicocele rupture have been diagnosed at the time of surgery when patients presenting with an acute scrotum were managed with immediate surgical exploration (8). The reported clinical features of a ruptured varicocele include scrotal swelling, pain and ecchymosis (11). As time passes, it can be expected that they will become fluctuant as the haematoma liquefies, as was the case with this patient.

Ultrasonography is the imaging modality of choice in the assessment of scrotal pathology (13). Two reports from

Japan have documented the ability of scrotal ultrasonography to correctly diagnose a ruptured varicocele, a rare cause of an acute scrotum (11, 12). The two patients diagnosed by scrotal ultrasonography were successfully managed conservatively, with one having elective varicocele ligation months later (12).

For patients presenting with an acute scrotal swelling, the differential diagnosis includes conditions such as incarcerated inguinal hernia, testicular torsion, testicular neoplasm, hydrocoele and spermatic cord tumour. An acute scrotal haematoma due to a ruptured varicocele should be included as a potential cause of an inguinoscrotal swelling, especially when there is a history of strenuous activity. When the clinical features mentioned above are present, ultrasonography with Doppler modes should be routinely employed to confirm the diagnosis.

While management guidelines are difficult to validate with such a rare condition, it is clear that initial conservative care can be successful and may allow for delayed varicocele ligation when the swelling has resolved. Early surgical intervention is appropriate when conservative measures fail or if there is diagnostic uncertainty. An inguinal approach is advisable as it allows for spermatic cord dissection outside of the haematoma and can be used to treat other potential pathology.

## REFERENCES

1. Bong GW. The adolescent varicocele: to treat or not to treat. *Urol Clin North Am* 2000; **43**: 509–515.
2. McKenney MG, Fietsam R. Spermatic cord hematoma: Case report and literature review. *Am Surg* 1996; **62**: 768–70.
3. Rolnick D. Spontaneous haematoma of spermatic cord. *Am J Surg* 1965; **109**: 519–20.
4. Bliss P. A case of spontaneous haematoma of the spermatic cord. *J R Nav Med Serv* 1957; **43**: 35–6.
5. Gilligan MS, Shah SO. Spontaneous idiopathic spermatic cord hematoma. *Conn Med* 1985; **49**: 293–4.
6. Lerman SH, Lerman PH. Spontaneous idiopathic hematoma of the spermatic cord: A report of 2 cases. *J Urol* 1981; **125**: 130–1.
7. Gordon JN, Aldoroty RA, Stone NN. A spermatic cord hematoma secondary to varicocele rupture from blunt abdominal trauma: A case report and review. *J Urol* 1993; **149**: 602–3.
8. Redman JF, Rountree GA, Bissada NA. Injuries to scrotal contents by blunt trauma. *Urology* 1976; **7**: 190–1.
9. Aliabadi H, Cass AS. Nontraumatic rupture of varicocele. *Urology* 1987; **29**: 421–2.
10. Bissett RD. Two cases of traumatic rupture of a varicocele. *J R Nav Med Serv* 1945; **31**: 177–8.
11. Nishiyama Y, Nagai A, Nasu Y, Watanabe M, Kusumi N, Monden K et al. Varicocele rupture due to sexual intercourse. *Int J Urol* 2005; **12**: 585–7.
12. Matsui Y, Utsunomiya N, Ichioka K, Ueda N, Yoshimura K, Terai A. Spontaneous rupture of varicocele testis associated with advanced pancreatic cancer. *Int J Urol* 2004; **11**: 1145–6.
13. Dogra VS, Gottlieb RH, Oka M, Rubens DJ. Sonography of the scrotum. *Radiology* 2003; **227**: 18–36.